

ACC CLINICAL EXPERT CONSENSUS DOCUMENT

American College of Cardiology Clinical Expert Consensus Document on Standards for Acquisition, Measurement and Reporting of Intravascular Ultrasound Studies (IVUS)

A Report of the American College of Cardiology
Task Force on Clinical Expert Consensus Documents
Developed in Collaboration with the European Society of Cardiology
Endorsed by the Society of Cardiac Angiography and Interventions

WRITING COMMITTEE MEMBERS

GARY S. MINTZ, MD, FACC and STEVEN E. NISSEN, MD, FACC, *Co-Chairs*

WILLIAM D. ANDERSON, MD, FACC
STEVEN R. BAILEY, MD, FACC
RAIMUND ERBEL, MD, FESC, FACC*
PETER J. FITZGERALD, MD, PhD, FACC
FAUSTO J. PINTO, MD, PhD, FESC, FACC*

KENNETH ROSENFELD, MD, FACC
ROBERT J. SIEGEL, MD, FACC
E. MURAT TUZCU, MD, FACC
PAUL G. YOCK, MD, FACC

TASK FORCE MEMBERS

ROBERT A. O'ROURKE, MD, FACC, *Chair*

JONATHAN ABRAMS, MD, FACC
ERIC R. BATES, MD, FACC
BRUCE R. BRODIE, MD, FACC
PAMELA S. DOUGLAS, MD, FACC
GABRIEL GREGORATOS, MD, FACC

MARK A. HLATKY, MD, FACC
JUDITH S. HOCHMAN, MD, FACC
SANJIV KAUL, MBBS, FACC
CYNTHIA M. TRACY, MD, FACC
DAVID D. WATERS, MD, FACC

WILLIAM L. WINTERS, JR., MD, MACC

TABLE OF CONTENTS

Preamble	1479
I. Introduction.....	1479
A. Organization of Committee and Evidence Review.....	1479
B. Purpose of This Document.....	1479
II. Physical Principles of IVUS Imaging	1480

III. Equipment for IVUS Examination	1480
A. Mechanical Systems.....	1480
B. Electronic Systems	1480
IV. IVUS Artifacts.....	1480
A. Non-Uniform Rotational Distortion (NURD) and Motion Artifacts.....	1480
B. Ring-Down, Blood Speckle, and Near Field Artifacts	1481
C. Obliquity, Eccentricity, and Problems of Vessel Curvature.....	1481
D. Problem of Spatial Orientation.....	1481
V. Controls for Image Acquisition.....	1481
A. Gain and TGC	1481
B. Compression and Rejection	1481
C. Time-Averaging and Persistence	1481
D. Gamma Curves	1482
VI. Acquisition and Display Techniques.....	1482
A. Manual and Motorized Interrogation	1482
B. Longitudinal Display (L-Mode).....	1482

When citing this document, the American College of Cardiology would appreciate the following citation format: Mintz GS, Nissen SE, Anderson WD, Bailey SR, Erbel R, Fitzgerald PJ, Pinto FJ, Rosenfeld K, Siegel RJ, Tuzcu EM, Yock PG. ACC Clinical Expert Consensus Document on Standards for the acquisition, measurement and reporting of intravascular ultrasound studies: a report of the American College of Cardiology Task Force on Clinical Expert Consensus Documents (Committee to Develop a Clinical Expert Consensus Document on Standards for Acquisition, Measurement and Reporting of Intravascular Ultrasound Studies [IVUS]). *J Am Coll Cardiol* 2001;37:1478-92.

*Official representatives of the European Society of Cardiology.

Address for reprints: This document is available on the ACC Website at www.acc.org. Reprints of this document are available for \$5.00 each by calling 800-253-4636 (U.S. only) or writing to the Resource Center, American College of Cardiology, Educational Services, 9111 Old Georgetown Road, Bethesda, MD 20814-1699.

C. Three-Dimensional Reconstruction	1482
D. Picture in a Picture Display	1482
VII. Definition of “Lesion” and “Reference” Segment	1483
VIII. Quantitative Measurements	1483
A. Border Identification	1483
B. Lumen Measurements	1484
C. EEM Measurements	1485
D. Atheroma Measurements	1485
E. Calcium Measurements	1485
F. Stent Measurements	1486
G. Reference Segment Measurements	1486
H. Remodeling	1486
I. Length Measurements	1486
IX. Qualitative Assessment	1486
A. Atheroma Morphology	1486
B. Dissections and Other Complications After Intervention	1487
C. Unstable Lesions and Ruptured Plaque	1487
D. Unusual Lesion Morphology (Aneurysms, Pseudoaneurysms, True vs. False Lumen)	1487
E. Ambiguous Lesions	1487
F. Special Disease Considerations	1488
1. Assessment of transplant vasculopathy	1488
2. Serial examination of progression/regression	1488
3. Aortic, carotid, and peripheral vascular disease	1488
4. Interventional target lesion assessment	1488
5. The restenotic lesion	1489
6. Vein graft disease	1489
7. Serial stent studies	1489
8. Radiation	1489
X. Specialized Analysis Techniques	1489
A. Radiofrequency–Backscatter	1489
B. Automated Edge Detection	1490
XI. Reporting of IVUS Studies	1490
A. Recommended Format and Minimum Content of Coronary IVUS Reports	1490
Technical Glossary	1490
Staff	1491
References	1491

PREAMBLE

The present document is an Expert Consensus Document that includes evidence about the standards for the acquisition, measurement, and reporting of intravascular ultrasound studies (IVUS). This document is intended to inform practitioners, payers, and other interested parties of the opinion of the American College of Cardiology (ACC) concerning evolving areas of clinical practice and/or technologies that are widely available or new to the practice community. Topics chosen for coverage by Expert Consensus Documents are so designed because the evidence base and experience with technology or clinical practice are not considered sufficiently well developed to be evaluated by the formal ACC/American Heart Association (AHA) Practice Guidelines process. Often, the topic is the subject of

considerable ongoing investigation. Thus, the reader should view the Expert Consensus Document as the best attempt of the ACC to inform and guide clinical practice in those areas where rigorous evidence may not yet be available or the evidence to date is not widely accepted. When feasible, Expert Consensus Documents include indications or contraindications. Some topics covered by Expert Consensus Documents will be addressed subsequently by the ACC/AHA Practice Guidelines Committee.

The Task Force on Clinical Expert Consensus Documents makes every effort to avoid any actual or potential conflicts of interest that might arise as a result of an outside relationship or personal interest of a member of the writing panel. Specifically, all members of the writing panel are asked to provide disclosure statements to inform the writing effort of all such relationships that might be perceived as real or potential conflicts of interest.

*Robert A. O'Rourke, MD, FACC
Chair, ACC Task Force on
Clinical Expert Consensus Documents*

I. INTRODUCTION

A. Organization of Committee and Evidence Review

The committee consisted of acknowledged experts in IVUS representing the ACC (10 members) and the European Society of Cardiology (2 members). Both the academic and private practice sectors were represented. The document was reviewed by four official reviewers nominated by the ACC, four reviewers representing the ACC Board of Governors and providing a practice perspective; seven content reviewers nominated by the Writing Committee, the ACC Cardiac Catheterization and Intervention Committee and Cardiovascular Imaging Committee, and two organizations—the European Society of Cardiology and the Society of Cardiac Angiography and Interventions. The document was approved for publication by the ACC Board of Trustees on January 9, 2001, and endorsed by the European Society of Cardiology and the Society of Cardiac Angiography and Interventions. This document will be considered current unless the Task Force revises or withdraws it from distribution.

B. Purpose of This Document

During the past decade, IVUS has become increasingly important in both clinical and research applications (1–6). However, it evolved without existing standards for the acquisition of studies, the measurement of images, and the reporting of results. The lack of standards has affected the ability of clinicians to communicate findings using a common language. Similarly, the literature has been confounded by ambiguous terminology and various alternative synonyms for similar structures and measurements. Accordingly, the current expert consensus committee was commissioned by the ACC, in collaboration with the European Society of Cardiology, to provide a framework for standardization of

nomenclature, methods of measurement, and reporting of IVUS results. The committee has sought to provide a logical and consistent approach to IVUS analysis in order to assist both clinicians and investigators.

II. PHYSICAL PRINCIPLES OF IVUS IMAGING

Medical ultrasound images are produced by passing an electrical current through a piezoelectric (pressure-electric) crystalline material (usually a ceramic) that expands and contracts to produce sound waves when electrically excited. After reflection from tissue, part of the ultrasound energy returns to the transducer, which produces an electrical impulse that is converted into the image. The beam remains fairly parallel for a distance (*near field*) and then begins to diverge (*far field*). The quality of ultrasound images is greater in the near field because the beam is narrower and more parallel, the resolution greater, and the characteristic backscatter (reflection of ultrasound energy) from a given tissue more accurate. The length of the near field is expressed by the equation $L = r^2 / \lambda$, where L is the length of the near field, r is the radius of the transducer, and λ is the wavelength. Therefore, larger transducers with lower frequencies are used for examination of large vessels to extend the near field into the region of diagnostic interest.

Image quality can be partially described by two important factors: *spatial resolution* and *contrast resolution*. The ability to discriminate small objects within the ultrasound image (*spatial resolution*) has two principal directions: *axial* (parallel to the beam—primarily a function of wavelength) and *lateral* (perpendicular to both the beam and the catheter—a function of wavelength and transducer size, or *aperture*). For a 20 to 40 MHz IVUS transducer, the typical resolution is 80 microns axially and 200 to 250 microns laterally. *Contrast resolution* is the distribution of the gray scale of the reflected signal and is often referred to as dynamic range. An image of low dynamic range appears as black and white with a few in-between gray scale levels; images at high *dynamic range* are often softer, with preserved subtleties in the image presentation.

As an ultrasound pulse encounters a boundary between two tissues—fat and muscle, for instance—the beam will be partially reflected and partially transmitted. The degree of reflection depends on the difference between the mechanical impedance of the two materials. For example, imaging of highly calcified structures is associated with acoustic shadowing: nearly complete reflection of the signal at the soft tissue/calcium interface. As the wave passes through many tissue interfaces, the energy is *attenuated* (reduced). Attenuation is a function of the tissue characteristics, the scattering of energy by small objects, and the absorption by tissue. Thus, only a small percentage of the emitted signal returns to the transducer. The received signal is converted to electrical energy and sent to an external signal processing system for amplification, filtering, scan-conversion, user-controlled modification, and finally, graphic presentation.

III. EQUIPMENT FOR IVUS EXAMINATION

There are two different types of IVUS transducers: the mechanically rotating transducer and the electronically switched multi-element array system. The first design is referred to as a “mechanical IVUS system,” and the latter a “solid-state design IVUS system.”

A. Mechanical Systems

A single rotating transducer is driven by a flexible drive cable at 1,800 rpm (30 revolutions per second) to sweep a beam almost perpendicular to the catheter. At approximately 1° increments, the transducer sends and receives ultrasound signals. The time delay and amplitude of these pulses provide 256 individual radial scans for each image. Mechanical transducer catheters require flushing with saline to provide a fluid pathway for the ultrasound beam, because even small air bubbles can degrade image quality. In most mechanical systems, the transducer spins within a protective sheath while the imaging transducer is moved proximally and distally. This facilitates smooth and uniform mechanical pullback.

B. Electronic Systems

Electronic systems use an annular array of small crystals rather than a single rotating transducer. The array can be programmed so that one set of elements transmits while a second set receives simultaneously. The coordinated beam generated by groups of elements is known as a synthetic aperture array. The image can be manipulated to focus optimally at a broad range of depths. The currently available electronic system provides simultaneous colorization of blood flow.

IV. IVUS ARTIFACTS

A. Non-Uniform Rotational Distortion (NURD) and Motion Artifacts

Non-uniform rotational distortion is unique to mechanical catheter systems and results from mechanical binding of the drive cable that rotates the transducer (7). This can occur for a number of reasons, including the presence of acute bends in the artery, tortuous guide catheter shapes, variance in manufacturing of the hub or driveshaft, excessive tightening of a hemostatic valve, kinking of the imaging sheath, or too small a guide catheter lumen. In an extreme situation, fracture of the drive cable can occur.

A distinct motion artifact can result from nonstable catheter position. Occasionally, the vessel moves before a complete circumferential image can be created. This results in cyclic deformation of the image.

In addition, both mechanical and solid state transducers can move as much as 5 mm between diastole and systole. This can preclude accurate assessment of arterial phenomena that depend on the cardiac cycle (i.e., arterial pulsation and compliance).

B. Ring-Down, Blood Speckle, and Near Field Artifacts

Ring-down artifacts are usually observed as bright halos of variable thickness surrounding the catheter. They are produced by acoustic oscillations in the transducer, which result in high-amplitude ultrasound signals that obscure the area immediately adjacent to the catheter. Ring-down artifacts are present in all medical ultrasound devices and create a zone of uncertainty adjacent to the transducer surface. Although time gain compensation (TGC) can be used to decrease this artifact, excessive ring-down suppression can reduce signals from true targets. In the solid state systems, the transducers are surface mounted, and ring-down is partially reduced by digital subtraction of a reference mask. If it is incorrectly performed, digital subtraction has the potential to remove real information or introduce false targets.

The intensity of the blood speckle increases (exponentially) as transducer frequency is increased and as blood flow velocity decreases. This phenomenon can limit the ability to differentiate lumen from tissue (especially soft plaque, neointima, and thrombus). This problem is exacerbated by flow stagnation or rouleaux formation, often most evident when the catheter is across a tight stenosis or within certain dissections (e.g., intramural hematomas). As with ring-down suppression, TGC manipulation to reduce blood speckle can reduce signals from real targets. Some operators flush contrast or saline through the guiding catheter to clear the lumen and help identify tissue borders. Computer-based imaging algorithms can also suppress or differentiate blood speckle from tissue.

C. Obliquity, Eccentricity, and Problems of Vessel Curvature

Current imaging techniques assume that the vessel is circular, the catheter is located in the center of the artery, and the transducer is parallel to the long axis of the vessel. However, both transducer obliquity and vessel curvature can produce an image giving the false impression that the vessel is elliptical. Transducer obliquity is especially important in large vessels and can result in an overestimation of dimensions and a reduction in image quality (8). The latter phenomenon occurs because the amplitude of the echo reflected from an interface depends, in part, on the angle at which the beam strikes the interface. The strongest signals are obtained when the catheter is coaxial within the vessel and when the beam strikes the target at a 90° angle. Therefore, lower image quality and errors in interpretation are more likely when the IVUS catheter is not parallel to the vessel wall.

D. Problem of Spatial Orientation

There is no absolute anterior, posterior, left and right orientation possible in IVUS images. However, with some systems, images can be rotated electronically to produce a constant orientation. For example, images of a left anterior

descending coronary can be electronically rotated so that the circumflex is positioned at 9 o'clock. With this orientation, the diagonal branches will arise from the left side of the image; and the septal branches will appear perpendicular to the diagonal branches. However, electronic rotation of the image is an electronic aid to interpretation and not a definitive standard. Side branches, visualized with both angiography and ultrasound, are extremely useful as landmarks in facilitating interpretation and comparisons. Some authors also describe the use of perivascular landmarks as important references for both axial position and tomographic orientation within the vessel. These landmarks include the pericardium, strands of muscle tissue, and the venous system.

V. CONTROLS FOR IMAGE ACQUISITION

System settings are very important in helping to interpret plaque characteristics. A glossary of terms and their definitions is appended.

A. Gain and TGC

Gain refers to amplification of the signal. Increasing the overall gain can compensate for a low sensitivity catheter, but at the expense of creating a more bistable (black and white) image with increased noise and decreased gray scale information.

Time gain compensation is a graduated adjustment of the amplitude of the signal at predetermined distances from the transducer, applied to balance intensity of the image, create even gain throughout the image, and compensate for attenuation in the far field. Lowering of near field gain is sometimes used to reduce near field artifacts or excessive backscatter from blood, but it may also attenuate and obscure signals from minimally reflective tissue (e.g., in-stent neointimal hyperplasia). Time gain compensation adjustments are specific only to certain mechanical scanners.

B. Compression and Rejection

There is no standard for setting the levels of compression and rejection, therefore, operators should adjust the settings until an optimal image with smooth gradation of gray levels is obtained. Rejection and compression can easily be set too high or too low, resulting in image artifacts. Rejection and compression adjustments are specific only to certain mechanical scanners.

C. Time-Averaging and Persistence

The limited signal-to-noise ratio of IVUS images makes them particularly amenable to noise reduction techniques. Much of the noise in ultrasound is randomly distributed, appearing as speckles in the image at different locations within each successive frame, while real reflectors (tissue) are present in the same location in consecutive frames. Averaging of successive frames will reduce the apparent intensity of noise; but it is always done at the expense of

time resolution, and it may blur real targets. Therefore, IVUS system designers commonly use a technique known as “persistence,” in which the image represents mostly the current frame (typically 60% to 90%) and a smaller percentage of the previous frame (10% to 40%). Thus, the displayed image is a “moving average” that includes prior frames. This technique can introduce objectionable motion artifacts.

D. Gamma Curves

Gamma curves control the relationship between the actual and the displayed gray scale. They are used primarily to present a more pleasing image, but they also affect dynamic range and qualitative and quantitative characteristics. If they are used excessively, gamma curve adjustments may result in measurement inaccuracies.

VI. ACQUISITION AND DISPLAY TECHNIQUES

Current practice requires that the patient be anticoagulated, usually with heparin, before inserting the guidewire into the coronary artery. Unless it is contraindicated, image acquisition should be performed after administering intracoronary nitroglycerin to avoid catheter-induced spasm.

A. Manual and Motorized Interrogation

There are two approaches to imaging: 1) motorized, or 2) manual interrogation. In either case, imaging should include careful uninterrupted imaging of the target segment, generally including at least 10 mm of distal vessel, the lesion site(s), and the entire proximal vessel back to the aorta. Many experts advocate that *motorized transducer pullback* be performed at a speed of 0.5 mm/s. Faster pullback speeds have the disadvantage of imaging focal pathology too quickly, but they are commonly employed for longer extracardiac vessels in order to minimize imaging times. Important advantages of motorized interrogation include steady catheter withdrawal to avoid imaging any segment too quickly and the ability to concentrate on the images without having to pay attention to catheter manipulation. Motorized pullbacks permit length and volumetric measurements and provide uniform and reproducible image acquisition for multicenter and serial studies. However, inadequate examination of important regions of interest can occur because the transducer does not remain for long at any specific site in the vessel.

Manual transducer pullback should be performed slowly, at a rate similar to motorized pullback. Advantages are the ability to concentrate on specific regions of interest by pausing the transducer motion at a specific location in the vessel. Disadvantages include the possibility of skipping over significant pathology by pulling the transducer too quickly or unevenly and the inability to perform precise length and volume measurements. Furthermore, antegrade and retrograde manual catheter movement can be confusing when the study is reviewed at a later date.

In interrogating aorto-ostial lesions it is important that

the guiding catheter be disengaged from the ostium. If it is not, the true aorto-ostial lumen may be masked by the catheter and, therefore, not identified.

B. Longitudinal Display (L-Mode)

An important limitation of IVUS is that only single cross-sectional images of the coronary artery are displayed, limiting spatial orientation and precluding facile assessment of the length and distribution of plaque and lesions. Motorized transducer pullback and digital storage of cross-sectional images are necessary for longitudinal (L-mode) imaging. In an L-mode display, computerized image reconstruction techniques display sets of “slices” taken from a single cut plane within each of a series of evenly spaced IVUS images to approximate the longitudinal appearance of the artery (9). To be meaningful, the cut plane should be through the center of mass of the artery or of the lumen, not arbitrarily through the center of the catheter, whose widely varying position within the vessel can arbitrarily affect the appearance of the artery.

There are major limitations of L-mode display, including the obligate straight reconstruction of the artery and the ability to display only a single arbitrary cut plane. Characteristic motion artifacts result in a “saw-tooth” appearance because of relative movement of the transducer and vessel, although ECG-triggered image acquisition may eliminate some of these artifacts (10,11). Excessive artifacts may result in misinterpretations by inexperienced users. Therefore, the L-mode should not be used for quantitative purposes.

C. Three-Dimensional Reconstruction

Three-dimensional reconstruction of IVUS involves the use of advanced computer rendering techniques to display a shaded or wire-frame image of the vessel and give the operator a view of the vessel in its entirety (12,13). Although many reconstruction algorithms are possible, all suffer from major limitations. The localization of tissue interfaces (surfaces) by the computer software is inherently arbitrary; this may or may not represent actual boundaries. Accordingly, routine use of three-dimensional methods cannot be recommended, although such techniques are promising and warrant future research.

D. Picture in a Picture Display

“Picture in picture” refers to the display of a fluoroscopic or angiographic image as a small window within the IVUS image. The major advantage of this approach is the ability to relate the location of the transducer to the actual IVUS images obtained at the site. A disadvantage is the relatively low quality of small angiographic images recorded on videotape and the difficulty in identifying the small transducer. In some systems, the angiographic image can be displayed as the larger image and the IVUS as the small window, but with similar disadvantages.

VII. DEFINITION OF “LESION” AND “REFERENCE” SEGMENT

Because coronary disease often appears to be more extensive by IVUS than by angiography, there are several problems in lesion and stenosis nomenclature (14–20). In some cases, a vessel segment will contain diffuse atherosclerosis, but no focal narrowings. In other cases, IVUS will reveal a number of discrete focal narrowings and a few more severe stenoses. Therefore, appropriate definitions of “lesion” and “reference segment” nomenclature require different methodology than commonly employed in angiography. Accordingly, for the purpose of this document, the following definitions will be used:

Proximal reference: The site with the largest lumen proximal to a stenosis but within the same segment (usually within 10 mm of the stenosis with no major intervening branches). This may not be the site with the least plaque.

Distal reference: The site with the largest lumen distal to a stenosis but within the same segment (usually within 10 mm of the stenosis with no intervening branches). This may not be the site with the least plaque.

Largest reference: The largest of either the proximal or distal reference sites.

Average reference lumen size: The average value of lumen size at the proximal and distal reference sites.

Lesion: A lesion represents accumulation of atherosclerotic plaque compared with a predefined reference.

Stenosis: A stenosis is a lesion that compromises the lumen by at least 50% by cross-sectional area (CSA) (compared with a predefined reference segment lumen).

Worst stenosis (T-1): The stenosis with the smallest lumen size.

Secondary stenoses (T-2, T-3, etc.): Lesions meeting the definition of a stenosis, but with lumen sizes larger than the worst stenosis.

In some cases, proper description of lesions and stenoses may require analysis of an entire segment with measurement of a number of image slices. In other cases, lesions, and especially stenoses, can be optimally represented by a single slice. Within a segment, there will always be a worst stenosis (T-1), but there can be multiple secondary stenoses (T-2, T-3, etc.). The worst stenosis cross-sectional image should be the slice with the smallest lumen, which may or may not represent the site with the largest atheroma. This site may differ slightly in location from its angiographic counterpart.

Pre- and post-intervention stenosis site selection and measurements should be performed in an identical fashion, recognizing that the exact location of the worst stenosis may change. For certain serial studies, the same anatomic image slice will be measured and compared (pre- vs. post-intervention or post-intervention vs. follow-up), although it may or may not represent the smallest lumen in both cases. The following sequence can be used to identify image slices on serial studies: 1) an image slice is selected from the first study, and the distance from this image slice to the closest

identifiable axial landmark (a fiducial point) is measured (using seconds or frames of videotape); 2) the second study is screened to identify this fiducial point, and the previously measured distance is used to identify the corresponding image slices on the second study; 3) vascular and perivascular markings (e.g., small side branches, venous structures, calcific and fibrotic deposits) are used to confirm slice identification. If necessary, studies should be analyzed side-by-side and the imaging runs studied frame-by-frame to ensure that the same anatomic slices correspond correctly.

In order to assess the morphology of the lesion or stenosis (i.e., the plaque composition, calcium, etc.), the entire lesion or stenosis should be surveyed, not just the worst stenosis image slice selected for measurement.

Efforts should be made to use the same reference sites before and after intervention unless the reference site is altered by an intervention during the procedure (i.e., incorporated into a stented or atherectomized segment).

In the case of multiple lesions within a single coronary segment, distinct lesions or stenoses require at least 5 mm between them. If not, then the disease should be considered a single long lesion.

VIII. QUANTITATIVE MEASUREMENTS

Measurements should be avoided if artifacts such as NURD are present or if the IVUS catheter is positioned obliquely (not parallel to the vessel long axis). Area measurements can be added to calculate volumes (Simpson's Rule).

A. Border Identification

It is important to recognize that all ultrasound techniques, including IVUS, require measurements to be performed at the leading edge of boundaries, never the trailing edge (Fig. 1). With few exceptions, the location of the leading edge is accurate and reproducible regardless of system settings or image-processing characteristics of different ultrasound scanners (21). Measurements at the trailing edge are inconsistent and frequently yield erroneous results.

In muscular arteries such as the coronary arteries, there are frequently three layers (22–27). The innermost layer consists of a complex of three elements: intima, atheroma (in diseased arteries), and internal elastic membrane. This innermost layer is relatively echogenic compared with the lumen and media. The trailing edge of the intima (which would correspond to the internal elastic membrane) cannot always be distinguished clearly. Moving outward from the lumen, the second layer is the media, which is usually less echogenic than the intima. In some cases the media may appear artifactually thin because of “blooming,” an intense reflection from the intima or external elastic membrane (EEM). In other cases the media can appear artifactually thick because of signal attenuation and the weak reflectivity of the internal elastic membrane. (In elastic arteries such as the carotid artery, the media is more echoreflexive because of the higher elastin content.) The third and outer layer

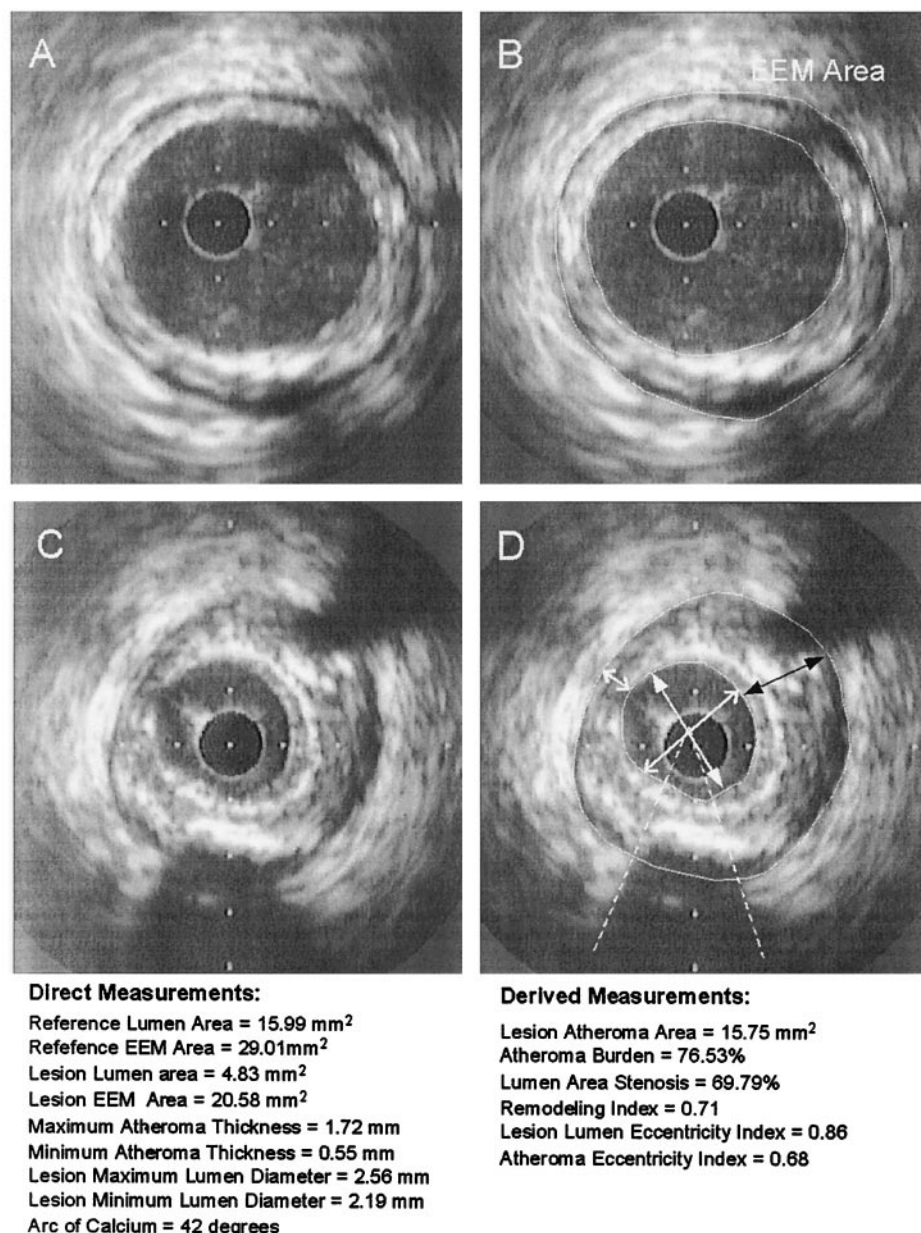


Figure 1. Example of commonly performed direct and derived IVUS measurements. **Panels A and B** illustrate the reference segment, whereas **panels C and D** represent the stenosis. In **Panel B**, the EEM and lumen areas are traced. In **panel D**, the minimum and maximum lumen diameters are illustrated using a double headed arrow (open and solid arrowheads, respectively). In **panel D**, the minimum and maximum atheroma thickness is also illustrated using double headed arrows (white for minimum and black for maximum). Also in **panel D**, the EEM and lumen areas are traced and the arc of calcification (dotted line) is shown. EEM = external elastic membrane.

consists of the adventitia and periadventitial tissues. There is no distinct boundary on IVUS images separating the true adventitia from surrounding perivascular tissues.

B. Lumen Measurements

Lumen measurements are performed using the interface between the lumen and the leading edge of the intima.

In normal segments, the intimal leading edge is easily resolved because the intima has thickened enough to be

resolved as a separate layer and has sufficiently different acoustic impedance from the lumen. Under such circumstances, the leading edge of the innermost echogenic layer should be used as the lumen boundary. Occasionally, particularly in younger normal subjects (e.g., post-transplantation), the vessel wall will have a single-layer appearance because the intima cannot be resolved as a discrete layer. In such cases, a thin, inner echolucent band corresponding to the intima and media is usually present and it is this boundary that should be measured. While

lumen boundaries defined in this manner may include the intima, the thickness of this layer will be $<160\ \mu\text{m}$ and will add negligible error to the lumen measurement.

Once the lumen border has been determined, the following lumen measurements can be derived. In all cases measurements are performed relative to the center of mass of the lumen, rather than relative to the center of the IVUS catheter:

Lumen CSA: The area bounded by the luminal border.

Minimum lumen diameter: The shortest diameter through the center point of the lumen.

Maximum lumen diameter: The longest diameter through the center point of the lumen.

Lumen Eccentricity: 1 [(maximum lumen diameter minus minimum lumen diameter) divided by maximum lumen diameter.]

Lumen area stenosis: (Reference lumen CSA minus minimum lumen CSA)/reference lumen CSA. The reference segment used should be specified (proximal, distal, largest, or average—see above).

Post-intervention (if dissection is present), it is important to state whether the lumen area is the true lumen or a combination of the true and false lumens.

C. EEM Measurements

A discrete interface at the border between the media and the adventitia is almost invariably present within IVUS images and corresponds closely to the location of the EEM. The recommended term for this measurement is *EEM CSA*, rather than alternative terms such as “vessel area” or “total vessel area.”

External elastic membrane circumference and area cannot be measured reliably at sites where large side branches originate or in the setting of extensive calcification because of acoustic shadowing. If acoustic shadowing involves a relatively small arc ($<90^\circ$), planimetry of the circumference can be performed by extrapolation from the closest identifiable EEM borders, although measurement accuracy and reproducibility will be reduced. If calcification is more extensive than 90° of arc, EEM measurements should not be reported. In addition, some stent designs may obscure the EEM border and render measurements unreliable.

Disease-free coronary arteries are circular, but atherosclerotic arteries may remodel into a non-circular configuration. If maximum and minimum EEM diameters are reported, measurements should bisect the geometric center of the vessel rather than the center of the IVUS catheter.

D. Atheroma Measurements

Because the leading edge of the media (the internal elastic membrane) is not well delineated, IVUS measurements cannot determine true histological atheroma area (the area bounded by the internal elastic membrane) (21). Accordingly, IVUS studies use the EEM and lumen CSA measurements to calculate a surrogate for true atheroma area,

the plaque plus media area. In practice, the inclusion of the media into the atheroma area does not constitute a major limitation of IVUS, because the media represents only a very small fraction of the atheroma CSA. We suggest that the term “plaque plus media (or atheroma)” be used and that the following measurements be performed:

Plaque plus media (or atheroma) CSA: The EEM CSA minus the lumen CSA.

Maximum plaque plus media (or atheroma) thickness: The largest distance from the intimal leading edge to the EEM along any line passing through the center of the lumen.

Minimum plaque plus media (or atheroma) thickness: The shortest distance from intimal leading edge to the EEM along any line passing through the luminal center of mass.

Plaque plus media (or atheroma) eccentricity: (Maximum plaque plus media thickness minus minimum plaque plus media thickness) divided by maximum plaque plus media thickness.

Plaque (or atheroma) burden: Plaque plus media CSA divided by the EEM CSA. The atheroma burden is distinct from the luminal area stenosis. The former represents the area within the EEM occupied by atheroma regardless of lumen compromise. The latter is a measure of luminal compromise relative to a reference lumen analogous to the angiographic diameter stenosis.

E. Calcium Measurements

Intravascular ultrasound is the most sensitive in vivo method for the detection of coronary calcium (28,29). Calcific deposits appear as bright echoes that obstruct the penetration of ultrasound, a phenomenon known as “acoustic shadowing.” Because high frequency ultrasound does not penetrate the calcium, IVUS can detect only the leading edge and cannot determine the thickness of the calcium. Calcium can also produce reverberations or multiple reflections that result from the oscillation of ultrasound between transducer and calcium and cause concentric arcs in the image at reproducible distances.

Calcium deposits are described qualitatively according to their location (e.g., lesion vs. reference) and distribution:

Superficial: The leading edge of the acoustic shadowing appears within the most shallow 50% of the plaque plus media thickness.

Deep: The leading edge of the acoustic shadowing appears within the deepest 50% of the plaque plus media thickness.

The arc of calcium can be measured (in degrees) by using an electronic protractor centered on the lumen. Because of beam-spread variability at given depths within the transmitted beam, this measurement is usually valid only to $\pm 15^\circ$. Semi-quantitative grading has also been described, which classifies calcium as absent or subtending 1, 2, 3, or 4 quadrants. The length of the calcific deposit can be measured using motorized transducer pullback.

F. Stent Measurements

Metallic stent struts are strong reflectors of ultrasound and, therefore, appear as echogenic points or arcs along the circumference of the vessel. Depending on the design, each stent has a slightly different appearance. Slotted-tube or multicellular stents appear as focal metallic points, whereas coiled stents appear as arcs of metal that subtend small sections of the vessel wall.

Strut apposition refers to the proximity of stent struts to the arterial wall (30–32). Good apposition is defined as sufficiently close contact to preclude blood flow between any strut and the underlying wall. Documentation of non-apposition can be enhanced by flushing saline or contrast from the guiding catheter to confirm the presence or absence of flow. The arc and/or length of non-apposition can be reported.

In imaging stents by IVUS, high gain settings should be avoided because the metallic struts are strong ultrasound reflectors and easily create side lobes (see Technical Glossary). Side lobes may obscure the true lumen and stent borders, interfering with area measurements and the assessment of apposition, dissection, etc. The stent area is measured by planimetry of the area bounded by the stent struts. If strut non-apposition is present, the stent area will be smaller than the lumen area. In the case of previously placed stents with superimposed neointimal proliferation, the stent area will be larger than the lumen area.

The following measurements are commonly reported:

Stent CSA: The area bounded by the stent border.

Minimum stent diameter: The shortest diameter through the center of mass of the stent.

Maximum stent diameter: The longest diameter through the center of mass of the stent.

Stent symmetry: [(maximum stent diameter minus minimum stent diameter) divided by maximum stent diameter.]

Stent expansion: The minimum stent CSA compared with the predefined reference area, which can be the proximal, distal, largest, or average reference area.

G. Reference Segment Measurements

Once the reference segments are selected, quantitative and qualitative assessment should be similar to the stenosis and include EEM, lumen, and plaque plus media measurements.

H. Remodeling

Vascular remodeling, originally described by Glagov *et al.* (33) from necropsy specimens, refers to the increase or decrease in EEM area that occurs during the development of atherosclerosis. By facilitating both the plaque and EEM area measurements, IVUS imaging permits *in vivo* assessment of vascular remodeling (34–40).

If EEM area increases during atheroma development, the process is termed “positive remodeling.” If the EEM decreases, the process is termed “negative” or “constrictive

remodeling.” In positive remodeling, the EEM area increase may *over-compensate* for increasing plaque area, resulting in an net increase in lumen size. Alternatively, remodeling can either: 1) exactly compensate for increasing plaque area, resulting in no change in lumen size, or 2) under-compensate for increasing plaque area, often termed *inadequate remodeling*.

An index that describes the magnitude and direction of remodeling is expressed as: lesion EEM CSA/reference EEM CSA. If the lesion EEM area is greater than the reference EEM area, positive remodeling has occurred, and the index will be >1.0 . If the lesion EEM area is smaller than the reference EEM area, negative remodeling has occurred, and the index will be <1.0 . A number of dichotomous definitions of remodeling have been proposed (34–40). The reference segment(s) used in studies of remodeling should be measured without any major intervening side branches. This relationship defines remodeling according to a comparison of the reference EEM and the lesional EEM. However, both reference and lesion sites may have undergone changes in EEM area during the atherosclerotic disease process. Accordingly, the evidence of remodeling derived from this index is indirect.

Direct evidence of remodeling can be derived only from serial changes in the EEM CSA that have been determined by two or more measurements obtained at different times. In this case, the slope of the line relating the change in EEM area to the change in plaque plus media (atheroma) area determines the direction and magnitude of remodeling. A slope >1.0 would indicate positive remodeling; whereas a slope <1.0 would indicate inadequate (incompletely compensatory) remodeling, a slope <0 (or reduction in EEM CSA) would indicate negative or constrictive remodeling.

Only direct evidence of remodeling (serial – post-intervention vs. follow-up measurements of EEM CSA or volume), not indirect indices, should be employed in studies of the restenotic process.

I. Length Measurements

Length measurements using IVUS can be performed using motorized transducer pullback (number of seconds \times pullback speed). This approach can be used to determine the length of a lesion, stenosis, calcium, or any other longitudinal feature.

IX. QUALITATIVE ASSESSMENT

A. Atheroma Morphology

Ultrasound images are fundamentally different from histology. Intravascular ultrasound cannot be used to detect and quantify specific histologic contents.

Soft (echolucent) plaques: The term “soft” refers not to the plaque’s structural characteristics, but rather to the acoustic signal that arises from low echogenicity. This is generally the result of high lipid content in a mostly cellular lesion (23–27,41,42). However, a zone of reduced echogenicity

may also be attributable to a necrotic zone within the plaque, an intramural hemorrhage, or a thrombus. Most soft plaques contain minimal collagen and elastin.

Fibrous plaques: These plaques have an intermediate echogenicity between soft (echolucent) atheromas and highly echogenic calcific plaques (23-27,41,42). Fibrous plaques represent the majority of atherosclerotic lesions. In general, the greater the fibrous tissue content, the greater the echogenicity of the tissue. Very dense fibrous plaques may produce sufficient attenuation or acoustic shadowing to be misclassified as calcified.

Calcific: See section on calcium measurements.

Mixed: Plaques frequently contain more than one acoustic subtype. Appropriate terminology for these plaques includes a number of descriptions such as "fibrocalcific," "fibrofatty," etc.

Thrombus: By IVUS, a thrombus is usually recognized as an intraluminal mass, often with a layered, lobulated, or pedunculated appearance (43,44). Thrombi may appear relatively echolucent or have a more variable gray scale with speckling or scintillation. Blood flow in "microchannels" may also be apparent within some thrombi. Stagnant blood flow can simulate a thrombus with a grayish-white accumulation of specular echoes within the vascular lumen. Injection of contrast or saline may disperse the stagnant flow, clear the lumen, and allow differentiation of stasis from thrombosis. However, none of these features is pathogenomic for thrombus, and the diagnosis of thrombus by IVUS should always be considered presumptive.

Intimal hyperplasia: The intimal hyperplasia characteristic of early in-stent restenosis often appears as tissue with very low echogenicity, at times less echogenic than the blood speckle in the lumen. Appropriate system settings are critical to avoid suppressing this relative non-echogenic material. The intimal hyperplasia of late in-stent restenosis often appears more echogenic.

B. Dissections and Other Complications After Intervention

Intravascular ultrasound is commonly employed to detect and direct the treatment of dissections and other complications after intervention (45-49). The classification of dissections into five categories is recommended:

Intimal: Limited to the intima or atheroma, and not extending to the media.

Medial: Extending into the media.

Adventitial: Extending through the EEM.

Intramural hematoma: An accumulation of blood within the medial space, displacing the internal elastic membrane inward and EEM outward. Entry and/or exit points may or may not be observed.

Intra-stent: Separation of neointimal hyperplasia from stent struts, usually seen only after treatment of in-stent restenosis.

The severity of a dissection can be quantified according to: 1) depth (into plaque—useful only in describing intimal dissections that do not reach the media); 2) circumferential

extent (in degrees of arc) using a protractor centered on the lumen; 3) length using motorized transducer pullback; 4) size of residual lumen (CSA); and 5) CSA of the luminal dissection. Additional descriptors of a dissection may include the presence of a false lumen, the identification of mobile flap(s), the presence of calcium at the dissection border, and dissections in close proximity to stent edges.

In a minority of patients, the dissection may not be apparent by IVUS, because of the scaffolding by the imaging catheter or because the dissection is located behind calcium. Usually, ultrasound occult dissections can be demonstrated by angiography.

C. Unstable Lesions and Ruptured Plaque

No definitive IVUS features define a plaque as vulnerable (38,44). However, necropsy studies demonstrated that unstable coronary lesions are usually lipid-rich with a thin fibrous cap. Accordingly, hypoechoic plaques without a well-formed fibrous cap are presumed to represent potentially vulnerable atherosclerotic lesions.

Ruptured plaques have a highly variable appearance by IVUS. In patients studied after an acute coronary syndrome, ultrasound imaging may reveal an ulceration, often with remnants of the ruptured fibrous cap evident at the edges of the ulcer. A variety of other appearances are common, including fissuring or erosion of the plaque surface. The following definitions are recommended:

Plaque ulceration: A recess in the plaque beginning at the luminal-intimal border, typically without enlargement of the EEM compared with the reference segment.

Plaque rupture: A plaque ulceration with a tear detected in a fibrous cap. Contrast injections may be used to prove and define the communication point.

The presence of thrombi may obscure IVUS detection of plaque fissuring or ulceration.

D. Unusual Lesion Morphology (Aneurysms, Pseudoaneurysms, True vs. False Lumen)

True aneurysm: A lesion that includes all layers of the vessel wall with an EEM and lumen area >50% larger than the proximal reference segment.

Pseudoaneurysm: Disruption of the EEM, usually observed after intervention.

True versus false lumen: A true lumen is surrounded by all three layers of the vessel-intima, media, and adventitia. Side branches communicate with the true, but not with the false lumen. A false lumen is a channel, usually parallel to the true lumen, that does not communicate with the true lumen over a portion of its length.

E. Ambiguous Lesions

Angiographically ambiguous lesions may include: 1) intermediate lesions of uncertain stenotic severity; 2) aneurysmal lesions; 3) ostial stenoses; 4) disease at branching sites; 5) tortuous vessels; 6) left main stem lesions; 7) sites with focal spasm; 8) sites with plaque rupture; 9) dissection after

coronary angioplasty; 10) intraluminal filling defects; 11) angiographically hazy lesions; and 12) lesions with local flow disturbances.

Intravascular ultrasound is frequently employed to examine lesions with the above characteristics, in some cases providing additional evidence useful in determining whether the stenosis is clinically significant (i.e., difficult to assess left main or borderline stenosis with continued symptoms). However, it must be emphasized that IVUS does not provide physiologic information per se.

F. Special Disease Considerations

1. Assessment of transplant vasculopathy. Coronary disease represents the major cause of death after the first year following transplantation and is often clinically silent because the heart is denervated. Ischemia by functional testing does not usually occur until the disease is advanced. Traditionally, angiography has been performed annually for surveillance, but the diffuse nature of the disease impairs detection. Accordingly, IVUS has emerged as the optimal method for early detection (50-53).

The definition of abnormal intimal thickness is controversial because the categorical classification of the continuous variable, intimal thickness, into normal or abnormal is inherently arbitrary. Most ultrasound studies define the threshold for transplant vasculopathy as an intimal thickness >0.5 mm.

Intravascular ultrasound protocols use a variety of approaches in the sampling of the coronary tree to detect transplant vasculopathy. Some centers randomly examine three or four sites at least 1 cm apart, but this method is limited by sampling errors and selection bias and is not suitable for serial analysis. Other approaches include site selection using predefined criteria to provide equal representation from each coronary segment. This usually captures the most severe intimal thickening, but it is also limited by selection bias. The most rigorous approach uses automated pullback to determine the entire volume of the EEM, lumen, and intima. This is labor-intensive but, if performed carefully, is the most accurate.

All the above methodologies have been used to compare follow-up and baseline studies. Serial images are often compared side by side, with angiographic and IVUS landmarks (side branches, pericardium, and cardiac veins) used to match sites. Alternatively, motorized pullback sequences can be compared, but some site matching is usually required because the fiducial points are often slightly different in sequences from various time points.

2. Serial examination of progression/regression. Angiographic studies of the regression/progression of atherosclerosis have generally shown minimal changes in luminal dimensions after anti-atherosclerotic treatment. Intravascular ultrasound, by virtue of its ability to depict the vessel wall, may be ideally suited for atherosclerosis regression/progression studies. Intravascular ultrasound often detects a much larger extent of disease than is evident by angiogra-

phy, frequently showing atherosclerosis in virtually all slices in pullbacks performed in patients with only a few stenoses (20).

Several large IVUS regression/progression studies are currently underway. Nearly all employ similar methodology. A target segment of a vessel is identified, and the ultrasound catheter is placed distal to a fiducial point such as a coronary branch. A motorized pullback is performed, typically at 0.5 mm/s. Using the fiducial side branch as the starting point, a long segment of vessel (25 to 50 mm) is analyzed, measuring the EEM, lumen, and plaque plus media area. Because a long pullback will contain at least 1,000 frames, analysis routinely subsamples at predefined intervals, typically every 1 mm. Studies show that plaque plus media volume calculated in this manner is highly reproducible and that serial studies can detect very small changes in atheroma volume.

3. Aortic, carotid, and peripheral vascular disease. Angiography has several unique limitations in defining the anatomy of peripheral vessels (54). Often, angulated or orthogonal views are not possible, foreshortening is not apparent and heavy calcification in arteries deep within the thorax, abdomen, pelvis, and thigh can obscure the vessel borders even after digital subtraction. The discovery of angiographically occult lesions by IVUS is common. There is often great disparity in size between large peripheral vessels and the relatively small angiographic catheters, which magnifies minor errors in calibration of radiographic measurements.

Analysis of IVUS in non-coronary vessels is similar to that of coronary arteries. Selection of catheter size, frequency, and type (mechanical or phased array) is based on the size and location of the vessel(s) to be examined and the size of the access sheath or guiding catheter. Unlike the coronary arteries in which near field resolution is the most crucial, the larger and more variable sizes of peripheral vessels make far field resolution equally important. In practice, lesion and reference sites are identified, assessed, and measured pre- and post-intervention similarly to coronary applications. The information is used to select appropriate devices and confirm results. The presence of diffuse disease, particularly common in the peripheral vasculature, may preclude identification of a truly "normal" reference site.

Several IVUS artifacts or limitations are more prominent in peripheral applications, particularly catheter obliquity. Other important problems include limited spatial resolution in very large vessels and severe acoustic shadowing by calcific plaque.

4. Interventional target lesion assessment. Target lesions can be assessed pre-intervention, sequentially during the procedure, post-intervention, and at follow-up (55,56). However, the axial location of the smallest target site may shift during each of these time points. If image slices do not have the same axial locations on sequential studies, it may be difficult to distinguish the effects of the intervention, plaque

distribution and remodeling, and shifting of plaque during the procedure. Planar analysis of only the smallest target site alone, before and after intervention, can produce the false impression of plaque compression or reduction. Volumetric analysis and averaging of multiple image slices (the sites with the smallest lumen at each time point) are both methods of compensating for the “migration” of the minimum lumen area. If only one target site is measured, its location should be specified. This is best accomplished by measuring the distance from a nearby well-identified axial landmark (i.e., side branch or unique calcium deposit) or by using vascular or perivascular markings.

5. The restenotic lesion. The restenotic lesion is the stenosis within the treated zone with the smallest lumen area at follow-up (55,56). The axial position of the restenotic lesion is usually different from the smallest pre-intervention or post-intervention target site. Thus, the image slice with the smallest luminal dimensions of the restenotic lesion cannot be directly compared to the image slice with the smallest lumen dimensions pre- or post-intervention. In-stent restenotic lesions require special consideration. The smallest lumen and the smallest stent area should be measured, but these may not be at the same axial location within the stented segment; and, in fact, the minimum lumen area may lie outside the stent.

To assess the restenotic *process*, the image slice with the smallest lumen area at follow-up is identified and compared with the same image slice on the post-intervention and pre-intervention studies, using measurements from a fiducial point or by identifying vascular or perivascular markings. Volumetric analysis of a length of arterial segment that encompasses all three locations (pre-, post- and restenotic) may also be useful in some situations. Three basic measurements in non-stented lesions are commonly reported—absolute values and change in the EEM, lumen, and plaque plus media areas or volumes. In stented lesions, at least two measurements are employed—absolute values of, and change in, stent and luminal dimensions. (Implantation of a stent can often obscure the measurement of EEM areas within the stented segment.) There can be changes in reference segment dimensions. Reference segment image slices with the same axial location on the serial studies should be identified for comparative analysis. (See earlier text for definitions of *Reference Segments*.)

6. Vein graft disease. In vein grafts, wall morphology and plaque characteristics are different from those in native coronary arteries. The bypass graft wall is free from the surrounding tissue and has no side branches. In situ veins do not have an EEM. However, vein grafts typically undergo “arterialization” with morphologic changes that include intimal fibrous thickening, medial hypertrophy, and lipid deposition. The EEM area is measured by tracing the outer border of the sonolucent zone. All other measurements including plaque plus media area and plaque burden, are calculated in a similar fashion to native coronary disease.

7. Serial stent studies. Serial studies (post-intervention vs. follow-up) can assess the mechanisms of in-stent restenosis, including the contributions of intimal hyperplasia and chronic stent recoil (57,58). Using automated pullback, the entire stent, lumen, and intimal hyperplasia (stent minus lumen) volumes are calculated post-implantation and at follow-up. The distribution of neointima can be analyzed by plotting intimal hyperplasia area over the length of the stent.

Using planar analysis, late luminal loss can be measured by comparing the minimum lumen CSA post-implantation and at follow-up. Chronic stent recoil can be measured by comparing the minimum stent CSA post-implantation with follow-up values. There can also be changes in reference segment dimensions. Reference segment image slices with the same axial location on the serial studies should be identified for comparative analysis. The distribution of reference segment changes (EEM, plaque plus media, and lumen areas) can be analyzed by plotting these parameters over the length of the reference segment that is contiguous with the stent edge.

8. Radiation. Intravascular ultrasound can be used to study the mechanisms and results of strategies for reducing restenosis, including brachytherapy (59). In non-stented lesions, serial (post-radiation vs. follow-up) analysis of lesion site and reference segment EEM, lumen, and plaque plus media volume is the most accurate approach. In stented lesions, measurements should include serial (post-radiation vs. follow-up) volumetric analysis of the stent, lumen, and intimal hyperplasia volumes and, where possible, measurement of serial analysis of EEM volumes as well. In addition, reference segment EEM, lumen, and plaque plus media volumes should be analyzed because radiation may affect these “non-treated” segments. The distribution of the neointima can be analyzed by plotting the intimal hyperplasia CSA over the length of the stent. Edge effects can be assessed by plotting changes in stent, lumen, and intimal hyperplasia CSA within the stent and changes in reference EEM, lumen, and plaque plus media area versus length. Qualitative morphology (i.e., apposition, dissections, etc.) should also be reported. The potential role of IVUS for dosimetry has not been defined and may depend on the radiation source.

X. SPECIALIZED ANALYSIS TECHNIQUES

A. Radiofrequency-Backscatter

Analysis of the raw radiofrequency (RF) data is a technique for assessing tissue properties (60). Among the various analysis parameters, the envelope of the RF signal is most commonly used for conventional image presentation. When the reflected ultrasound signal is analyzed in terms of its frequency components, a power spectrum results. This represents the magnitudes of all the frequencies within the returned signal. In vitro studies suggest that a detailed analysis of backscattered RF data may offer an objective and reproducible method of categorizing wall morphology and

plaque components. It remains uncertain whether spectral analysis of unprocessed data is reliable and unaffected by the various sources of error during in vivo imaging (angle dependency, blood noise) and should be considered a research tool.

B. Automated Edge Detection

The main objective of automated edge detection in IVUS imaging is to extract the relevant structural surface information such as lumen-intima border and/or media-adventitia border (10). This process includes the enhancement of image features and segmentation (separation of the image into its constituent parts). The gray level of a single pixel does not have sufficient information to assign that pixel to a structure. Therefore, the analysis of the spatial distribution of gray levels (multiple pixels and sub-images) is required for edge detection, but no method has found widespread acceptance. Edge detection and textural analysis should be considered as research tools, and they always require visual confirmation.

XI. REPORTING OF IVUS STUDIES

A. Recommended Format and Minimum Content of Coronary IVUS Reports

A written report for the IVUS examination should be generated. The report helps to communicate relevant information and becomes an important part of the patient's medical record where it may pertain to clinical, legal, or fiscal issues. Although the length and complexity of the report will vary greatly depending on the needs of different operators and institutions, a minimum content should be included:

- 1) Appropriate patient demographic information and date—reference to the accompanying angiographic and/or interventional report;
- 2) The indication for the procedure;
- 3) Brief description of the IVUS procedure, including the equipment used, the level of anticoagulation achieved, and the coronary arteries imaged;
- 4) Basic findings of the IVUS pullback, including any measurements that were performed such as minimum lumen diameter, minimum stent area, or plaque burden;
- 5) Any notable morphological plaque features such as dissection, calcium, or thrombus;
- 6) Changes in therapy that resulted from the information provided by IVUS; and
- 7) IVUS-related complications and any consequent therapy.

A more complete report should also include the analysis of three cardinal image slices—a distal reference segment, a worst target site, and a proximal reference segment. Lumen and EEM areas, calculated plaque plus media area, plaque burden, and area stenosis should be reported. If a stent is present, minimum stent area, an index of stent symmetry, and a description of strut apposition should be included.

TECHNICAL GLOSSARY

Aperture: The active part of the transducer that emits and/or receives ultrasound waves. Resolution and near field size can be directly related to the aperture; with increasing aperture size, the near field can be longer, thereby improving the axial resolution.

Blood speckle: The ultrasound reflection from aggregated blood cells.

Compress: A control that regulates the dynamic compression and affects gray scale and overall gain. In general, the higher the compression setting, the more black and white the image will appear.

Diffraction: The bending of waves around edges.

Dynamic range: The range of gray scale that is displayed between the weakest and the strongest targets. It is usually expressed in decibels (dB). A large or broad dynamic range is a favorable image characteristic. The dynamic range for IVUS is typically 17 to 55 dB.

Echogenicity: The tendency of a tissue to reflect ultrasound. The higher the echogenicity, the brighter the tissue will appear.

Far field: The region where the ultrasound beam diverges and resolution decreases.

Frequency: The number of sound cycles in a given time period. Frequency is inversely related to wavelength. Ultrasound waves with higher frequency (shorter wavelengths) are reflected from smaller objects. A higher frequency ultrasonic beam has greater resolution; but because a larger percentage of higher-frequency ultrasound is reflected, penetration decreases.

Gray scale: The ability of a system to record both bright and weak echoes in varying shades of gray. The number of gray scale levels is a measure of the dynamic range.

Integrated backscatter: Power (amplitude) measurements of the received backscatter signal.

Near field: The zone where the beam width is approximately the same as the transducer diameter, resulting in optimal resolution.

Rejection: A means of eliminating noise from the image by filtering low-amplitude signals.

Reverberations: An artifact represented by secondary, false echoes of the same structure. This gives the false impression of a second interface twice as far from the transducer as the first structure.

Radiofrequency (RF): Data after being converted from ultrasound to electrical signals, but before being processed, are in the RF range of electromechanical energy. Analysis of RF signals may give rise to tissue characterization in IVUS.

Resolution: The ability to discriminate or identify two objects that are close together.

Shadowing: An artifact representing weakness or absence of signals located beyond structures (e.g., calcium, stent struts) with high echo-reflectivity. This artifact can hinder imaging beyond strong reflectors.

Side lobes: Extraneous beams of ultrasound that are

generated from the edges of the individual transducer elements and are not in the direction of the main ultrasonic beam.

Tissue characterization: An approach that uses ultrasound to identify the physiologic and/or pathologic composition of biological tissue.

Ultrasound: Sound waves having a frequency >20,000 cycles per second (i.e., above the audible range). For medical diagnostic purposes, ultrasound frequencies in the range of millions of cycles per second (MHz) are used.

Velocity: The velocity at which sound travels through human soft tissue; this is fairly constant at approximately 1,540 m/s.

STAFF

Christine W. McEntee, Executive Vice President
Lisa Bradfield, Manager, Document Development

REFERENCES

- Bom N, Lancee CT, Van Egmond FC. An ultrasonic intracardiac scanner. *Ultrasonics* 1972;10:72-6.
- Yock PG, Linker DT, Angelsen BA. Two-dimensional intravascular ultrasound: technical development and initial clinical experience. *J Am Soc Echocardiogr* 1989;2:296-304.
- Hodgson JM, Graham SP, Savakus AD, et al. Clinical percutaneous imaging of coronary anatomy using an over-the-wire ultrasound catheter system. *Int J Card Imaging* 1989;4:187-93.
- Tobis JM, Mallery J, Mahon D, et al. Intravascular ultrasound imaging of human coronary arteries in vivo. Analysis of tissue characterizations with comparison to in vitro histological specimens. *Circulation* 1991;83:913-26.
- Nissen SE, Gurley JC, Grines CL, et al. Intravascular ultrasound assessment of lumen size and wall morphology in normal subjects and patients with coronary artery disease. *Circulation* 1991;84:1087-99.
- Di Mario C, Gorge G, Peters R, et al. Clinical application and image interpretation in intracoronary ultrasound. Study Group on Intracoronary Imaging of the Working Group of Coronary Circulation and of the Subgroup on Intravascular Ultrasound of the Working Group of Echocardiography of the European Society of Cardiology. *Eur Heart J* 1998;19:207-29.
- ten Hoff H, Korbijn A, Smith TH, Klinkhamer JF, Bom N. Imaging artifacts in mechanically driven ultrasound catheters. *Int J Card Imaging* 1989;4:195-9.
- Di Mario C, Madretsma S, Linker D, et al. The angle of incidence of the ultrasonic beam: a critical factor for the image quality in intravascular ultrasonography. *Am Heart J* 1993;125:442-8.
- Gil R, von Birgelen C, Prati F, Di Mario C, Ligthart J, Serruys PW. Usefulness of three-dimensional reconstruction for interpretation and quantitative analysis of intracoronary ultrasound during stent deployment. *Am J Cardiol* 1996;77:761-4.
- Bruining N, von Birgelen C, Di Mario C, et al. Dynamic Three-Dimensional Reconstruction of ICUS Images Based on an ECG-Gated Pull-Back Device. In: *Computers in Cardiology*. Los Alamitos, CA: Institute of Electrical and Electronics Engineers Computer Society, 2000:633-6.
- Dhawale PJ, Griffin N, Wilson DL, Hodgson JM. Calibrated 3-D Reconstruction of Intracoronary Ultrasound Images With Cardiac Gating and Catheter Motion Compensation. In: *Computers in Cardiology*. Washington, DC: Institute of Electrical and Electronics Engineers Computer Society, 1992:31-4.
- Evans JL, Ng KH, Wiet SG, et al. Accurate three-dimensional reconstruction of intravascular ultrasound data. Spatially correct three-dimensional reconstructions. *Circulation* 1996;93:567-76.
- Rosenfield K, Losordo DW, Ramaswamy K, et al. Three-dimensional reconstruction of human coronary and peripheral arteries from images recorded during two-dimensional intravascular ultrasound examination (see comments). *Circulation* 1991;84:1938-56.
- St Goar FG, Pinto FJ, Alderman EL, Fitzgerald PJ, Stadius ML, Popp RL. Intravascular ultrasound imaging of angiographically normal coronary arteries: an in vivo comparison with quantitative angiography. *J Am Coll Cardiol* 1991;18:952-8.
- Maheswaran B, Leung CY, Gutfinger DE, et al. Intravascular ultrasound appearance of normal and mildly diseased coronary arteries: correlation with histologic specimens. *Am Heart J* 1995;130:976-86.
- Hermiller JB, Buller CE, Tenaglia AN, et al. Unrecognized left main coronary artery disease in patients undergoing interventional procedures. *Am J Cardiol* 1993;71:173-6.
- Tuzcu EM, Hobbs RE, Rincon G, et al. Occult and frequent transmission of atherosclerotic coronary disease with cardiac transplantation. Insights from intravascular ultrasound. *Circulation* 1995;91:1706-13.
- Erbel R, Ge J, Bockisch A, et al. Value of intracoronary ultrasound and Doppler in the differentiation of angiographically normal coronary arteries: a prospective study in patients with angina pectoris. *Eur Heart J* 1996;17:880-9.
- Mintz GS, Painter JA, Pichard AD, et al. Atherosclerosis in angiographically "normal" coronary artery reference segments: an intravascular ultrasound study with clinical correlations. *J Am Coll Cardiol* 1995;25:1479-85.
- Topol EJ, Nissen SE. Our preoccupation with coronary luminology. The dissociation between clinical and angiographic findings in ischemic heart disease. *Circulation* 1995;92:2333-42.
- Wong M, Edelstein J, Wollman J, Bond MG. Ultrasonic-pathological comparison of the human arterial wall. Verification of intima-media thickness. *Arterioscler Thromb* 1993;13:482-6.
- Fitzgerald PJ, St. Goar FG, Connolly AJ, et al. Intravascular ultrasound imaging of coronary arteries. Is three layers the norm? *Circulation* 1992;86:154-8.
- Metz JA, Yock PG, Fitzgerald PJ. Intravascular ultrasound: basic interpretation. *Cardiol Clin* 1997;15:1-15.
- Lockwood GR, Ryan LK, Gotlieb AI, et al. In vitro high resolution intravascular imaging in muscular and elastic arteries. *J Am Coll Cardiol* 1992;20:153-60.
- Gussenhoven EJ, Essed CE, Lancee CT, et al. Arterial wall characteristics determined by intravascular ultrasound imaging: an in vitro study. *J Am Coll Cardiol* 1989;14:947-52.
- Potkin BN, Bartorelli AL, Gessert JM, et al. Coronary artery imaging with intravascular high-frequency ultrasound. *Circulation* 1990;81:1575-85.
- Nishimura RA, Edwards WD, Warnes CA, et al. Intravascular ultrasound imaging: in vitro validation and pathologic correlation. *J Am Coll Cardiol* 1990;16:145-54.
- Mintz GS, Douek P, Pichard AD, et al. Target lesion calcification in coronary artery disease: an intravascular ultrasound study. *J Am Coll Cardiol* 1992;20:1149-55.
- Tuzcu EM, Berkhalp B, De Franco AC, et al. The dilemma of diagnosing coronary calcification: angiography versus intravascular ultrasound. *J Am Coll Cardiol* 1996;27:832-8.
- Goldberg SL, Colombo A, Nakamura S, Almadoro Y, Maiello L, Tobis JM. Benefit of intracoronary ultrasound in the deployment of Palmaz-Schatz stents. *J Am Coll Cardiol* 1994;24:996-1003.
- Nakamura S, Colombo A, Gaglione A, et al. Intracoronary ultrasound observations during stent implantation. *Circulation* 1994;89:2026-34.
- Colombo A, Hall P, Nakamura S, et al. Intracoronary stenting without anticoagulation accomplished with intravascular ultrasound guidance. *Circulation* 1995;91:1676-88.
- Glagov S, Weisenberg E, Zarins CK, Stankunavicius R, Koletts GJ. Compensatory enlargement of human atherosclerotic coronary arteries. *N Engl J Med* 1987;316:1371-5.
- Hermiller JB, Tenaglia AN, Kisslo KB, et al. In vivo validation of compensatory enlargement of atherosclerotic coronary arteries. *Am J Cardiol* 1993;71:665-8.
- Losordo DW, Rosenfield K, Kaufman J, Pieczek A, Isner JM. Focal compensatory enlargement of human arteries in response to progressive atherosclerosis. In vivo documentation using intravascular ultrasound. *Circulation* 1994;89:2570-7.
- Pasterkamp G, Wensing PJ, Post MJ, Hillen B, Mali WP, Borst C. Paradoxical arterial wall shrinkage may contribute to luminal narrow-

- ing of human atherosclerotic femoral arteries. *Circulation* 1995;91:1444-9.
37. Mintz GS, Kent KM, Pichard AD, Satler LF, Popma JJ, Leon MB. Contribution of inadequate arterial remodeling to the development of focal coronary artery stenoses. An intravascular ultrasound study. *Circulation* 1997;95:1791-8.
38. Nishioka T, Luo H, Eigler NL, Berglund H, Kim CJ, Siegel RJ. Contribution of inadequate compensatory enlargement to development of human coronary artery stenosis: an in vivo intravascular ultrasound study. *J Am Coll Cardiol* 1996;27:1571-6.
39. Schoenhagen P, Ziada KM, Kapadia SR, Crowe TD, Nissen SE, Tuzcu EM. Extent and direction of arterial remodeling in stable versus unstable coronary syndromes: an intravascular ultrasound study. *Circulation* 2000;101:598-603.
40. Pasterkamp G, Schoneveld AH, van der Wal AC, et al. Relation of arterial geometry to luminal narrowing and histologic markers for plaque vulnerability: the remodeling paradox. *J Am Coll Cardiol* 1998;32:655-62.
41. Hodgson JM, Reddy KG, Suneja R, Nair RN, Lesnfsky EJ, Sheehan HM. Intracoronary ultrasound imaging: correlation of plaque morphology with angiography, clinical syndrome and procedural results in patients undergoing coronary angioplasty. *J Am Coll Cardiol* 1993;21:35-44.
42. Rasheed Q, Dhawale PJ, Anderson J, Hodgson JM. Intracoronary ultrasound-defined plaque composition: computer-aided plaque characterization and correlation with histologic samples obtained during directional coronary atherectomy. *Am Heart J* 1995;129:631-7.
43. Siegel RJ, Ariani M, Fishbein MC, et al. Histopathologic validation of angioscopy and intravascular ultrasound. *Circulation* 1991;84:109-17.
44. Kearney P, Erbel R, Rupprecht HJ, et al. Differences in the morphology of unstable and stable coronary lesions and their impact on the mechanisms of angioplasty. An in vivo study with intravascular ultrasound. *Eur Heart J* 1996;17:721-30.
45. Losordo DW, Rosenfield K, Pieczek A, Baker K, Harding M, Isner JM. How does angioplasty work? Serial analysis of human iliac arteries using intravascular ultrasound. *Circulation* 1992;86:1845-58.
46. Potkin BN, Keren G, Mintz GS, et al. Arterial responses to balloon coronary angioplasty: an intravascular ultrasound study. *J Am Coll Cardiol* 1992;20:942-51.
47. Braden GA, Herrington DM, Downes TR, Kutcher MA, Little WC. Qualitative and quantitative contrasts in the mechanisms of lumen enlargement by coronary balloon angioplasty and directional coronary atherectomy. *J Am Coll Cardiol* 1994;23:40-8.
48. van der Lugt A, Gussenhoven EJ, Stijnen T, et al. Comparison of intravascular ultrasonic findings after coronary balloon angioplasty evaluated in vitro with histology. *Am J Cardiol* 1995;76:661-6.
49. Honye J, Mahon DJ, Jain A, et al. Morphological effects of coronary balloon angioplasty in vivo assessed by intravascular ultrasound imaging. *Circulation* 1992;85:1012-25.
50. Pinto FJ, Chenzbraun A, Botas J, et al. Feasibility of serial intracoronary ultrasound imaging for assessment of progression of intimal proliferation in cardiac transplant recipients. *Circulation* 1994;90:2348-55.
51. Rickenbacher PR, Pinto FJ, Chenzbraun A, et al. Incidence and severity of transplant coronary artery disease early and up to 15 years after transplantation as detected by intravascular ultrasound. *J Am Coll Cardiol* 1995;25:171-7.
52. Yeung AC, Davis SF, Hauptman PJ, et al. Incidence and progression of transplant coronary artery disease over 1 year: results of a multicenter trial with use of intravascular ultrasound. Multicenter Intravascular Ultrasound Transplant Study Group. *J Heart Lung Transplant* 1995;14:S215-220.
53. Tuzcu EM, De Franco AC, Goormastic M, et al. Dichotomous pattern of coronary atherosclerosis 1 to 9 years after transplantation: insights from systematic intravascular ultrasound imaging. *J Am Coll Cardiol* 1996;27:839-46.
54. Isner JM, Rosenfield K, Losordo DW, et al. Percutaneous intravascular US as adjunct to catheter-based interventions: preliminary experience in patients with peripheral vascular disease. *Radiology* 1990;175:61-70.
55. Mintz GS, Popma JJ, Pichard AD, et al. Arterial remodeling after coronary angioplasty: a serial intravascular ultrasound study. *Circulation* 1996;94:35-43.
56. Kimura T, Kaburagi S, Tamura T, et al. Remodeling of human coronary arteries undergoing coronary angioplasty or atherectomy. *Circulation* 1997;96:475-83.
57. Hoffmann R, Mintz GS, Dussaillant GR, et al. Patterns and mechanisms of in-stent restenosis. A serial intravascular ultrasound study. *Circulation* 1996;94:1247-54.
58. Rosenfield K, Schainfeld R, Pieczek A, Haley L, Isner JM. Restenosis of endovascular stents from stent compression. *J Am Coll Cardiol* 1997;29:328-38.
59. Sabate M, Serruys PW, van der Giessen WJ, et al. Geometric vascular remodeling after balloon angioplasty and beta-radiation therapy: a three-dimensional intravascular ultrasound study. *Circulation* 1999;100:1182-8.
60. Linker DT, Kleven A, Gronningsaether A, Yock PG, Angelsen BA. Tissue characterization with intra-arterial ultrasound: special promise and problems. *Int J Card Imaging* 1991;6:255-63.